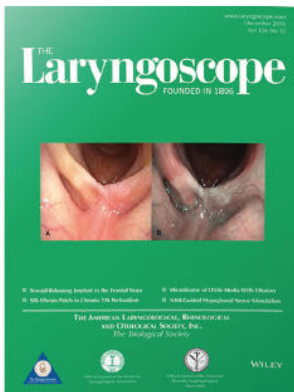



Premiere Publications from The Triological Society

Read all three of our prestigious publications, each offering high-quality content to keep you informed with the latest developments in the field.




THE Laryngoscope FOUNDED IN 1896

Editor-in-Chief: Michael G. Stewart, MD, MPH

The leading source for information in head and neck disorders.

Laryngoscope.com




Laryngoscope Investigative Otolaryngology

Open Access

Editor-in-Chief: D. Bradley Welling, MD, PhD, FACS

Rapid dissemination of the science and practice of otolaryngology-head and neck surgery.

InvestigativeOto.com



ENTtoday

A publication of the Triological Society


Editor-in-Chief: Alexander Chiu, MD

Must-have timely information that Otolaryngologist-head and neck surgeons can use in daily practice.

Enttoday.org

WILEY

Development of Three-Dimensional Laryngostroboscopy for Office-Based Laryngeal Diagnostics and Phonosurgical Therapy

Philipp P. Caffier, MD, PhD ; Tadeus Nawka, MD, PhD; Ahmed Ibrahim-Nasr, MD;
Björn Thomas, Dipl-Ing; Holger Müller, Dipl-Ing; Seo-Rin Ko, MD; Wen Song, MD;
Manfred Gross, MD, PhD; Sebastian Weikert, MD

Objective: To develop a three-dimensional (3D) laryngostroboscopic examination unit, compare the optic playback quality in relation to established 2D procedures, and report the first case series using 3D rigid laryngostroboscopy for diagnosis and management of laryngotracheal diseases.

Study Design: Laboratory study, prospective case series.

Methods: The optical efficacy of newly developed rigid 3D endoscopes was examined in a laboratory setting. Diagnostic suitability was investigated in 100 subjects (50 male, 50 female) receiving 2D high-definition (HD) and 3D laryngostroboscopy. Two of the subjects subsequently underwent 3D-assisted office-based transoral phonosurgery under local anesthesia. Main outcome measures were comparative visualization of laryngotracheal pathologies, influence on preoperative planning, and evaluation of prognostic factors for the outcome of phonosurgical interventions.

Results: Three-dimensional endostroboscopic procedures were effectively optimized to establish an examination protocol for all-day clinical use. Office-based 3D laryngostroboscopy was successfully applied in subjects with normal anatomy (n = 10) and various laryngotracheal findings (n = 90). In comparison to 2D HD videolaryngostroboscopy, the 3D view offered enhanced visualization of laryngotracheal anatomy, with qualitatively improved depth perception and spatial representation. In organic pathologies, this resulted in a more precise indication of phonosurgical procedures, increased accuracy in surgical planning, facilitated office-based endoscopic surgery, and better evaluation of prognostic factors for the outcome of phonosurgical interventions.

Conclusion: Three-dimensional laryngostroboscopy proved to increase the understanding of functional and surgical anatomy. Its application has enormous potential for improving the diagnostic value of laryngoscopy, surgical precision in laryngotracheal interventions, tissue preservation, and methods of teaching.

Key Words: 3D laryngostroboscopy, endoscopic evaluation, diagnostic procedures, laryngotracheal pathology, functional anatomy, phonosurgical planning.

Level of Evidence: N/A.

Laryngoscope, 00:000-000, 2018

INTRODUCTION

After initial visualization of vocal fold movements and laryngeal pathologies using mirrors inserted into the mouth and throat,¹⁻³ indirect laryngoscopy for diagnostic examination in today's office-based ear-nose-throat (ENT) and phoniatic clinical routine is performed via endoscopes.⁴⁻⁷ Different types of endoscopes are available: transorally applied rigid laryngoscopes

and transnasally applied flexible nasopharyngoscopes.⁸⁻¹⁰ Application of these two-dimensional (2D) laryngeal examination procedures using stroboscopic methods results in visualization of vocal fold movements in slow motion and allows precise examination.¹¹⁻¹³ However, all commercially available endoscopes for indirect laryngoscopy are only monoscopic. Thus, in laryngoscopy there currently is no depth information available. Tangential views of the medial surface of the glottis limit the diagnostic sensitivity¹⁴; therefore, endoscope image does not reach the full significance of a stereomicroscope observation.¹⁵ This disadvantage becomes a problem, especially with regard to unclear and difficult-to-assess findings.¹⁶ In addition, operating ENT physicians and phoniaticians are accustomed to high-resolution stereoscopic vision while working with the surgical microscope. As a result, many are reluctant to forego the 3D representation in office-based endoscopic applications.^{17,18} The direct laryngoscopy, which permits stereoscopic examination by the surgical microscope, cannot be used in voice diagnostics because it requires dorsiflexion of the head and general anesthesia with intubation narcosis or jet ventilation.¹⁹⁻²¹ Thus, this

From the Department of Audiology and Phoniatics, Charité-University Medicine Berlin (P.P.C., T.N., A.I.-N., S.-R.K., W.S., M.G., S.W.); and the XION GmbH (B.T., H.M.), Berlin, Germany

Editor's Note: This Manuscript was accepted for publication April 6, 2018.

This research project was part of the Central Innovation Program for SMEs in Germany and funded by the German Ministry of Economic Affairs and Energy (BMWi). Coauthors Björn Thomas and Holger Müller are employees of XION GmbH and contributed considerably to the technical development of the 3D system. The authors have no other funding, financial relationships, or any conflicts of interest to disclose.

Send correspondence to Philipp P. Caffier, MD, Department of Audiology and Phoniatics, Charité-University Medicine Berlin, Campus Charité Mitte, Charitéplatz 1, D-10117 Berlin, Germany. E-mail: philipp.caffier@charite.de.

DOI: 10.1002/lary.27260

diagnostic procedure is more effortful, complex, uncomfortable, invasive, and riskier for the patient. In addition, the anesthesia makes it impossible to observe the gross respiratory vocal fold movements from the phonation to the respiratory position and vice versa, as well as the fine phonatory vibrations of the vocal folds during vocalization.

Three-dimensional endoscopy is a promising development in the field of diagnostic and interventional otorhinolaryngology. Although the literature describes the benefits of using a high-definition (HD) 3D endoscope in endonasal and skull base surgery,^{22–25} and although it is quite well established in laparoscopic surgery,^{26,27} 3D technology was not used for laryngoscopic procedures until now. There is only one case study that examines the use of 3D endoscopy in evaluation and treatment; it describes three patients with subglottic and tracheal pathology and the unique inherent advantages of 3D compared with conventional 2D endoscopy.²⁸ With this exception, there is no literature about the use of 3D endoscopy or 3D stroboscopy in laryngology. Previous development approaches did not go beyond the experimental stage due to the significant technical difficulties associated with the application and because of unavailable or too expensive technologies. Recent progress in the semiconductor industry has made the construction of such a 3D high-performance laryngoscope appear technically and economically realistic for the first time. Therefore, the present work should examine from a technical as well as clinical point of view to what extent new diagnostic and therapeutic possibilities arise in this new laryngeal examination. The aims of our investigations were to develop a 3D laryngostroboscopic examination unit, compare the optic playback quality in relation to established 2D procedures, and report the first case series examining the use of 3D indirect laryngostroboscopy in the diagnosis and management of laryngotracheal pathology.

MATERIALS AND METHODS

At first, a stereoscopic laryngoscope with two optical channels was constructed (XION GmbH, Berlin, Germany). The initial investigations comprised basic diagnostic testing of the newly developed rigid 3D endoscopes. For this purpose, comparative measurements of the playback quality were made with different endoscope specifications concerning, for example, the position of the two optical channels with respect to different distances and angles to each other, illumination, and miniaturization. These examinations of optical efficacy were conducted in a laboratory setting.

Subsequently, 3D stroboscopy was established as an additional feature to increase the functional significance of the 3D-based diagnostic endoscopic procedure. The integration of a stroboscopy system poses a particular challenge because the exposure periods are very short, and thus the illumination and sensor sensitivity may reach their limits. The 3D stroboscope uses light-emitting diode flashes (LED), which are automatically synchronized with the vibration of the vocal folds at a frequency reduced by 1 Hz, allowing the examiner to observe vocal fold oscillations during phonation in apparent slow motion.

After implementation of a flicker-free 3D stroboscopy, the suitability of the new diagnostic system was investigated in 100

larynges (50 male, 50 female) of patients presenting in the outpatient clinic of the department of audiology and phoniatrics at Charité–University Medicine Berlin, Germany. This study was approved by our institutional review board. All subjects received standard voice function diagnostics and commonly established rigid 2D HD videolaryngostroboscopy, followed by rigid 3D laryngostroboscopy. Two patients subsequently underwent 3D-assisted office-based transoral phonosurgery under local anesthesia.

The main laryngoscopic evaluation criteria were the appearance of superficial mucosa, tissue morphology, and function of respiratory vocal fold mobility. Digital 3D videostroboscopy was activated via foot switch to visualize the vocal fold vibrations during phonation. As in 2D stroboscopy, results were considered suspicious when the vocal folds showed reduced or absent mucosal wave propagation, as well as in cases of reduced or eliminated phonatory vibration. Exemplary examinations of the vibrational properties of the vocal folds with different subglottic pressures, pitches, registers, and intensities were carried out. Main outcome measures were the comparative visualization of laryngotracheal pathology, its influence on preoperative planning for surgical procedures, and evaluation of prognostic factors for the outcome of phonosurgical interventions.

RESULTS

The 3D laryngostroboscopic examination system consisted of various newly developed components such as high-performance image processor, 3D camera head, sterile adapter, and stereoscopic laryngoscope, which were supplemented by commercially available accessories such as fiberoptic cable, microphone, LED light source, and 3D monitor. To achieve the required high-imaging performance and miniaturization, a new optical setup was established that ensured perfect illumination and extremely high optical resolution. The imaging performance was very homogeneous over the entire image field. The requirement of a high degree of miniaturization also posed considerable challenges for mechanical development and construction. Accordingly, all mechanical components of the 3D laryngoscope had to be newly developed. The 3D laryngoscope was constructed with a small outer diameter to make the examination of patients easy and comfortable. Essential system components and the principle of 3D laryngoscopy are shown schematically in Figure 1.

Based on the test results, various engineering improvements were made during the course of the experiments. The basic diagnostic testing of the 3D endoscopes with different specifications finally resulted in the following optimized technical settings: 50- to 70-mm normal working distance (system is focusable, suitable for other working distances), 70-degree viewing angle (prism at tip of laryngoscope), 8-mm outer diameter of laryngoscope shaft with two integrated optical channels, 3-mm interchannel distance (stereo base, defines depth perception), 38-degree field of view (aperture), and 1.3× digital zoom (optional magnification). The outcome of the basic diagnostic testing with this configuration revealed positive results with excellent image quality. The automated video processing includes image interpolation, measurement and control of image

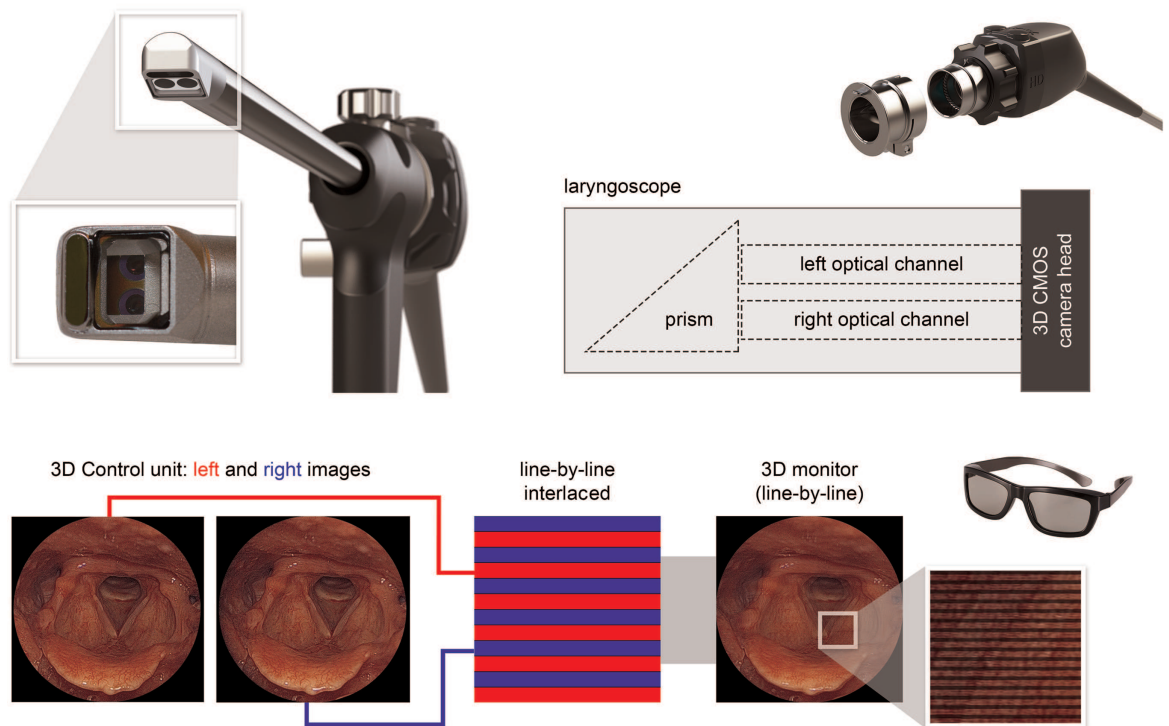


Fig. 1. Schema of essential components and principle of 3D laryngoscopy system. Upper row: stereoscopic laryngoscope with two optical channels, sterile adapter, 3D camera head. Lower row: 3D control unit, 3D monitor, polarized glasses. Images from the left and right optical channel are recorded separately, then horizontally sliced at the pixel level (interlaced) and displayed on a 3D monitor using the line-by-line method. The output image is perceived as a 3D picture by wearing polarized glasses, which do not impair off-screen acuity or evaluation of 2D procedures for comparison purposes. 2D = two dimensional; 3D = three dimensional.

parameters, and methods for improving subjectively perceived image quality. The comparison of the 3D optic playback quality exposed clear enhancement in relation to the established 2D procedures due to the additional depth effect with realistic spatial representation.

Subsequently, the development of a stable, reliable, and flicker-free 3D stroboscopy was successful, realizing the integration of sufficient 3D evaluation of vocal folds' mucosal wave propagation. The glottal cycle can be illustrated as a montage of video frames by clipping the area

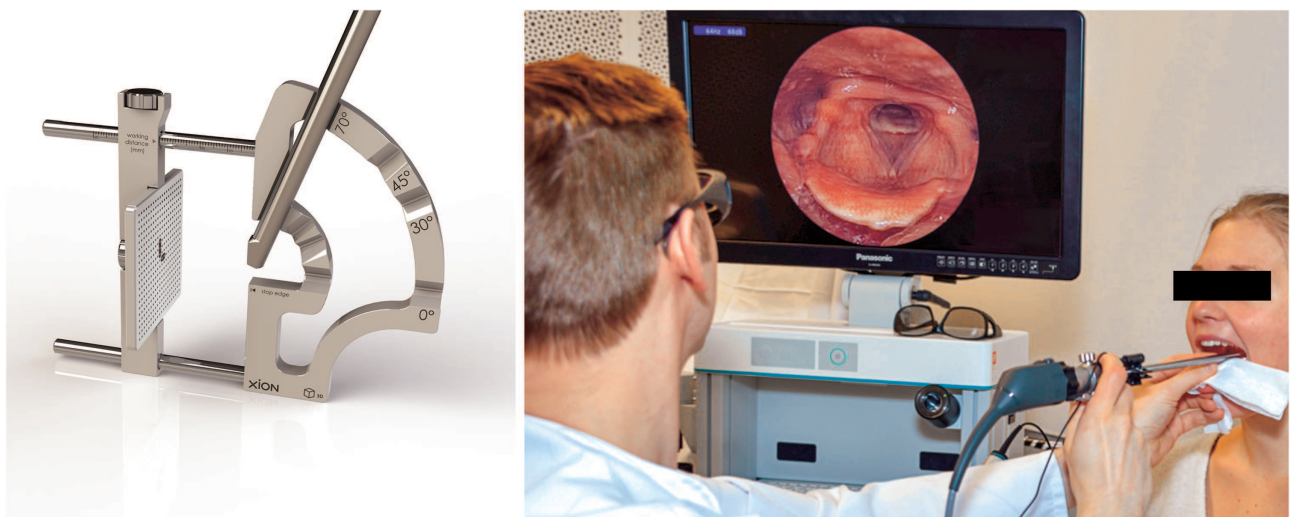


Fig. 2. Three-dimensional laryngostroboscopic system for office-based laryngeal diagnostics and phonosurgical therapy. Left: Calibration device with correctly placed stereoscopic laryngoscope. Right: Clinical use of the final system after calibration in a healthy female subject.

TABLE I.
Patient Characteristics*

Characteristics	Number of All Patients	% of Total Group (n = 100)	Number of Male Patients	% of Male Group (n = 50)	Number of Female Patients	% of Female Group (n = 50)
Gender						
Male	50	50.0%	–	–	–	–
Female	50	50.0%	–	–	–	–
Age Years (mean ± SD)	47 ± 18	–	50 ± 17	–	44 ± 19	–
Pathology classification						
Normal anatomy	10	10%	5	10%	5	10%
Functional dysphonia	3	3%	1	2%	2	4%
Organic dysphonia	90	90%	45	90%	45	90%
Rosen & Murry I	20	20%	16	32%	4	8%
Rosen & Murry II	29	29%	11	22%	18	36%
Rosen & Murry III	10	10%	5	10%	5	10%
Rosen & Murry IV	31	31%	13	26%	18	36%
Organic diagnosis						
Leukoplakia	2	2%	2	4%	0	0%
Glottal CIS/carcinoma	11	11%	9	18%	2	4%
Papillomatosis	7	7%	5	10%	2	4%
Marginal edema	3	3%	0	0%	3	6%
Reinke's edema	4	4%	0	0%	4	8%
Vocal fold polyp	6	6%	2	4%	4	8%
Vocal fold nodules	4	4%	1	2%	3	6%
Vocal fold cyst	4	4%	3	6%	1	2%
Vocal fold scars	7	7%	5	10%	2	4%
Varix cordis	1	1%	0	0%	1	2%
Granuloma	6	6%	4	8%	2	4%
Laryngitis	4	4%	1	2%	3	6%
Laryngocele	1	1%	1	2%	0	0%
Vocal fold paresis	11	11%	4	8%	7	14%
Spasmodic dysphonia	2	2%	2	4%	0	0%
Vocal fold atrophy	2	2%	1	2%	1	2%
Sulcus vocalis	7	7%	3	6%	4	8%
Glottal web/ synechia	2	2%	1	2%	1	2%
Laryngotracheal stenosis	6	6%	3	6%	3	6%

*Unless otherwise specified, data expressed as number of subjects and percentage of group.

Pathology classification according to Rosen & Murry²⁹: I = epithelium (e.g., leukoplakia, hyperkeratosis), CIS = carcinoma in situ, carcinoma, papillomatosis; II: lamina propria, e.g., Reinke's edema, polyps, cysts, scars, vascular malformation; III: arytenoid, e.g., granuloma, infection; IV: other, including movement disorders, hypo-/atrophy, malformation (e.g., as sulcus or glottal web).

of interest and assembling the frames as a series of glottal images. The montage image is ready for automated analysis and allows the 3D assessment of frequency, shape, amplitude, and phases (opening, closing, closed) of the vocal fold vibration. Also, pathologic vibration can be analyzed if periodic. An examination protocol for all-day clinical use of the final version of our 3D laryngostroboscopic examination unit was established. The 3D system is ready for application after a short and automatic adjustment procedure. The adjustment device can be used for various rigid endoscopes with different viewing angles and working distances (Fig. 2, left). Simultaneously, white balance is adjusted automatically during the 3D calibration procedure. The clinical use of the final version of the newly developed 3D system is shown in Figure 2 (right).

Finally, we successfully examined the application of 3D laryngostroboscopy in 100 patients (50 male, 50 female; 47 ± 18 years [mean ± standard deviation]). The total population consisted of 10 subjects with normal laryngeal anatomy, as well as 90 patients with organic dysphonia and various underlying laryngotracheal findings. Patient characteristics, pathology classification according to Rosen and Murry,²⁹ and a listing of all diagnoses are shown in Table I.

In comparison to clinical 2D HD laryngostroboscopy, the 3D view offered in all patients enhanced visualization of laryngotracheal anatomy with qualitatively improved depth perception and spatial representation. This allowed for correct assessment of the true position and motion of the vocal folds, especially in complex, unclear, traumatic, or preoperative findings. To recreate

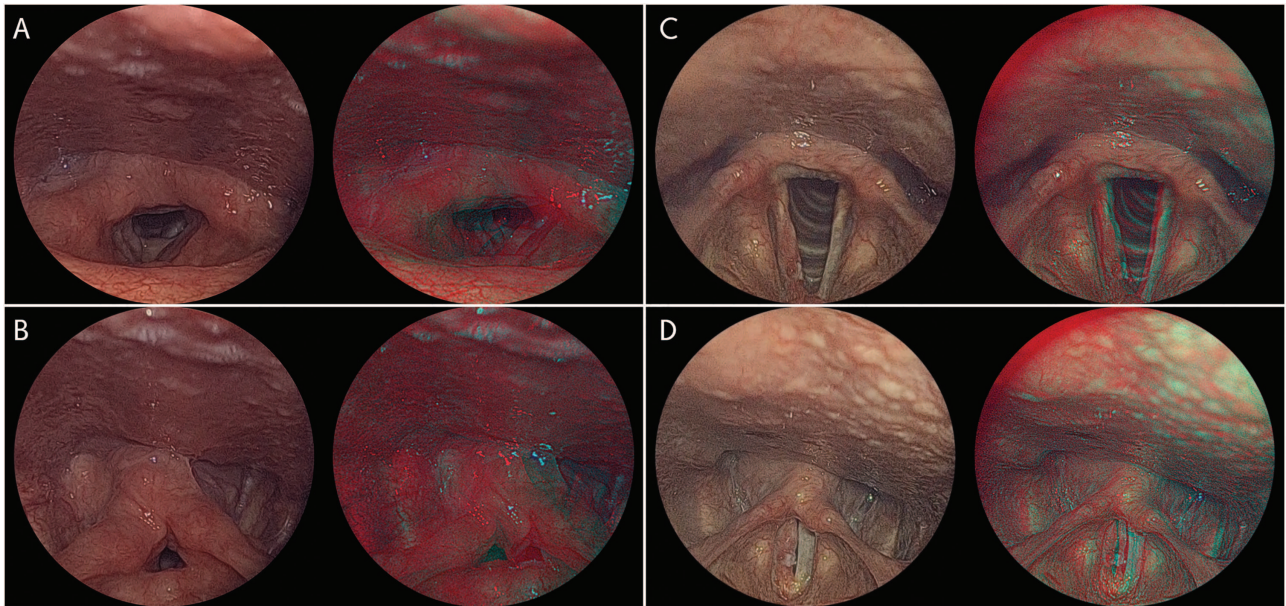


Fig. 3. Comparison between 2D high-definition and 3D images (left/right) in videolaryngostroboscopic diagnostics. (Red–cyan glasses are recommended to view the 3D images correctly.) Left column (A, B): 27-year-old Syrian civil war refugee with aphonia after laryngeal trauma due to bomb explosion. The standard 2D diagnostics shows glottal insufficiency and an unclear level of vocal fold residuals, resulting in more imprecise indication of phonosurgical augmentation. The new 3D tool offers a realistic depth perception and spatial representation with precise determination of corresponding glottal structures, resulting in an increased accuracy of surgical planning and better preoperative evaluation of prognostic factors for the outcome of the augmentation procedure. Right column (C, D): 58-year-old salesman with recurrent dysphonia after subepithelial laser cordectomy of the right vocal fold due to squamous cell carcinoma (pT1a). Two-dimensional and 3D laryngoscopy display a polypoid solid tumor of unknown malignancy. Conventional 2D and new 3D stroboscopy both reveal preserved phonatory vibration, making it unlikely that the possible recurrence is growing into deeper levels of the vocal fold. Three-dimensional stroboscopy improves the accuracy of surgical planning. After tissue-conserving tumor excision, the pathological examination provided the diagnosis of an inflammatory granulation polyp. 2D = two dimensional; 3D = three dimensional.

the 3D effect in this article, we blended the two original images of both optical channels (one for each eye) into a single anaglyph 3D picture. In anaglyph 3D viewing, the stereoscopic effect is achieved by encoding the two images with differently colored filters, typically red and cyan. Therefore, red–cyan glasses are required for the readers to experience the 3D effect in our figures. An example in a patient with unclear level of vocal fold residuals after laryngeal trauma is illustrated in Figure 3 (A, B). It turned out that the combination of stroboscopy and 3D endoscopy substantially increased the value of the new visualization system, especially in the evaluation of (pre)malignant changes. All suspicious cases with reduced or absent mucosal wave propagation, as well as reduced or eliminated phonatory vibration, were easily detected. The value of 3D stroboscopy as a screening device in laryngoscopically dubious lesions is exemplarily shown in Figure 3 (C, D).

Apart from these diagnostic procedures, one female patient with spasmodic dysphonia and one male patient with laryngeal granuloma each received office-based transoral phonosurgery under local anesthesia using 3D-assisted rigid videolaryngostroboscopy. The pre-, intra-, and postoperative status of both subjects is depicted in Figure 4 and Figure 5. The visualization and high resolution of the operative field provided a very detailed view of the underlying pathology and all anatomical

structures. The stereoscopic representation resulted in an improvement concerning spatial orientation, safety, and efficacy of the surgical procedure. The more realistic depth perception facilitated the endoscopic surgery and had a positive effect on intraoperative maneuverability and control. The operation time and the physical strain in terms of handling, ergonomics, and weight were in both cases similar to the standard 2D-assisted transoral procedure.

In general, the use of the new 3D system resulted in a more precise indication of phonosurgical procedures in patients with organic pathologies, increased accuracy in surgical planning, facilitated office-based endoscopic surgery, and better evaluation of prognostic factors for the outcome of phonosurgical interventions.

DISCUSSION

To our knowledge, this is the first report on the successful development of 3D laryngostroboscopy, and also the first description of a case series in otolaryngological literature examining the use of rigid 3D endostroboscopy in office-based diagnostics and phonosurgical therapy of laryngotracheal pathologies. Thus far, there have only been software developments, with the goal of calculating 3D vocal fold images from 2D recordings using high-speed cameras and laser projection systems.³⁰ This approach may be suitable for specific scientific questions

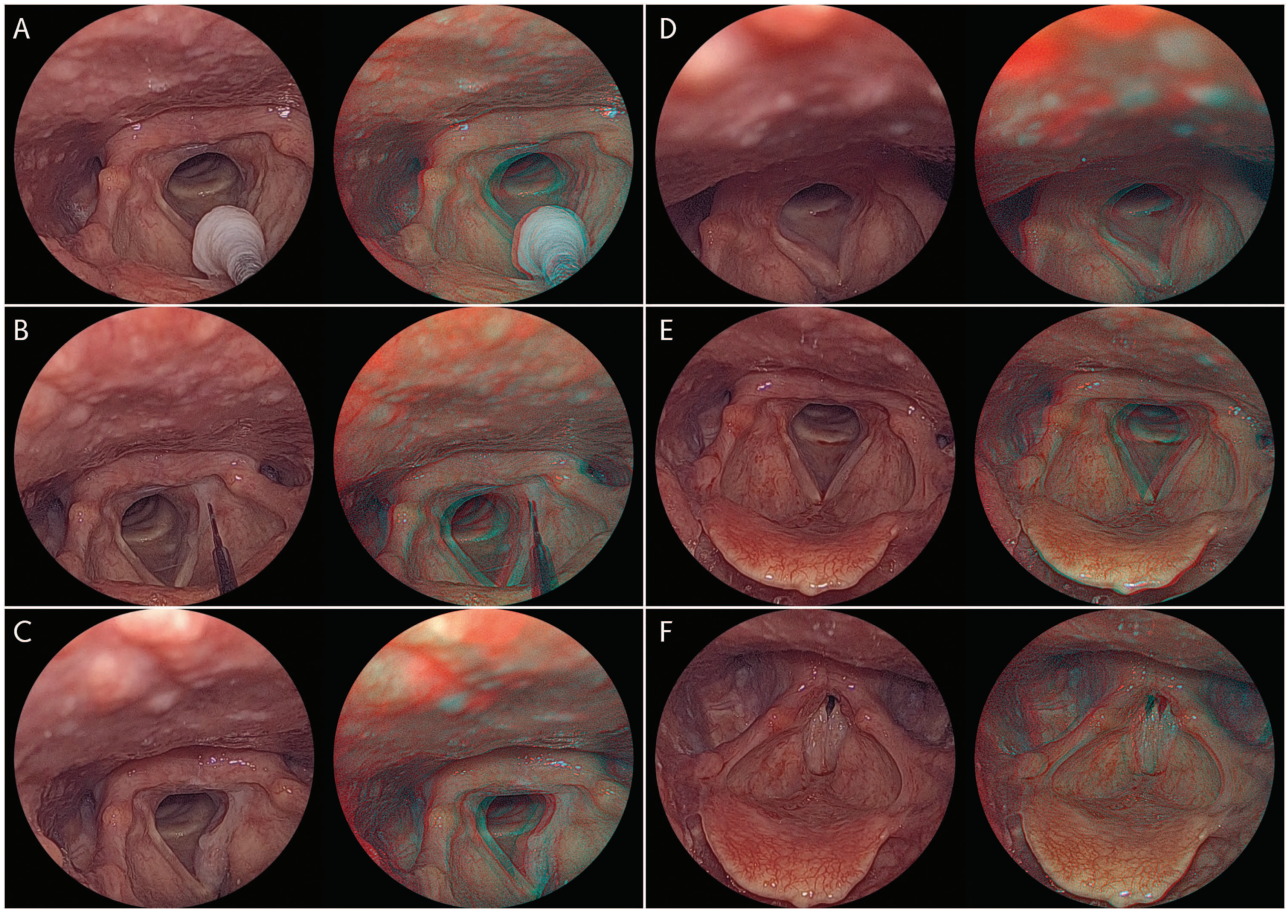


Fig. 4. Comparison between 2D high-definition and 3D images (left/right) in a 77-year-old female pensioner with spasmodic dysphonia, receiving injection of 2 international units botulinum toxin A (Botox, Allergan, Dublin, Ireland) in both thyroarytenoid muscles. (Red–cyan glasses are recommended to view the 3D images correctly.) (A) Preoperative application of local anesthesia (cotton swab soaked in a solution of 10 milliliter tetra caine 1%, adrenaline 6 drops, tacholiquine 6 drops). (B) Transoral insertion of bended injection needle. (C, D) Intraoperative procedure of intramuscular injection into left/right vocal fold. (E, F) Postoperative status 5 minutes after injection. 2D = two dimensional; 3 = three dimensional

but not for daily clinical routine. Practical application was only described in a case study by Reilly et al.²⁸ using flexible 3D laryngobronchoscopy. Apart from that, Kawaida et al.³¹ introduced a pseudo-3D visualizing technique providing binocular vision via horizontal image-shifting display method. This system digitally processed ordinary video signals obtained with a video camera connected to a direct videolaryngoscope, allowing pseudo-3D stereoendoscopic laryngosurgery.

Because rigid laryngoscopes are constructed with angled viewing directions,^{32,33} relatively narrow field of view, and higher magnification than other endoscopes, they are in general not easy to manufacture. In a stereoscopic laryngoscope, there are significantly higher demands on the performance and adjustment of the two optical channels. This is particularly true because a very high-image quality must be achieved. Thus, a mutual mechanical displacement of both image channels of a few micrometers is visible in stereo images. The optical and optomechanical problems known from stereoendoscopic cinematography were solved during the development of the 3D laryngoscope at a highly miniaturized

level. Thus, a stereoscopic laryngoscope is available for the first time.

After optimizing the technical configurations and establishing the examination protocol for all-day clinical use, the feasibility of the new 3D technology was examined on 100 patients during a pilot phase. High-quality video sequences were produced that underline the potential of 3D laryngoscopy. In comparison with the 2D HD laryngoscopy, most 3D recordings were self-explanatory in making the diagnosis of laryngotracheal findings safer due to more realistic depth and spatial visualization. These results are in line with the evaluation of findings in other medical disciplines, which have longer histories of using 3D endoscopy, especially in skull base and laparoscopic surgery.^{23–27} However, Van Gompel et al.³⁴ demonstrated a loss of field of view when using 0° 3D rigid endoscopes compared to 2D endoscopy. In contrast, our 3D laryngoscopes showed the same, or even an enlarged, field of view compared to 2D procedures, giving an excellent central and peripheral vision with high resolution of laryngeal, perilaryngeal, and more distant structures.

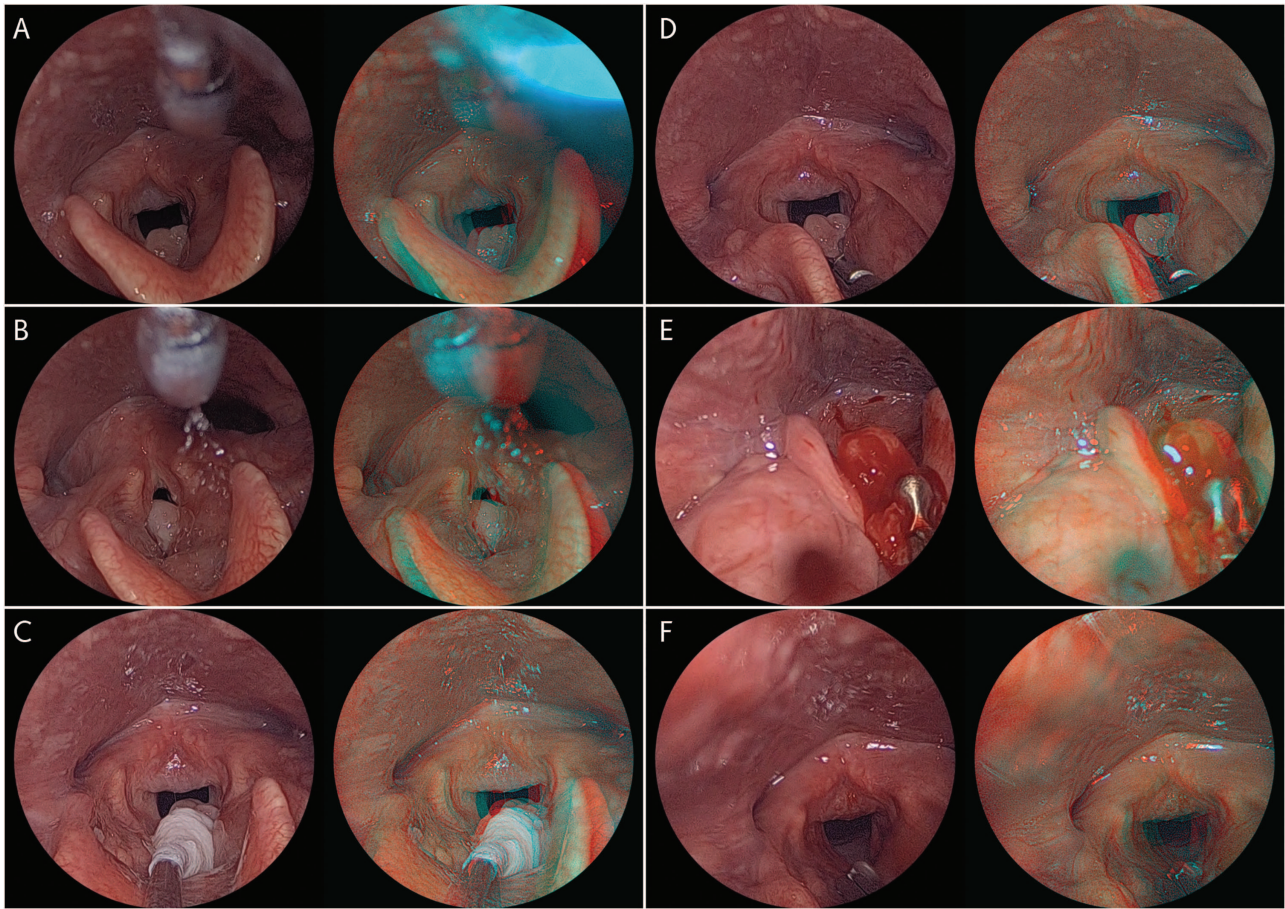


Fig. 5. Comparison between 2D high-definition and 3D images (left/right) in a 48-year-old manager with dysphonia due to recurrent laryngeal granuloma receiving excision of a large granulomatous polyp of the left vestibular fold. (Red–cyan glasses are recommended to view the 3D images correctly.) (A, B, C) Preoperative application of local anesthesia (spray and cotton swab). (D) Transoral insertion of a curved forceps and grasping of the granuloma. (E) Intraoperative procedure during granuloma extraction. (F) Postoperative status directly after excision with significant voice improvement. 2D = two dimensional; 3D = three dimensional.

In addition to the benefit of 3D laryngoscopy while observing the general anatomy and gross respiratory vocal fold movements, the newly developed flicker-free 3D stroboscopy allowed the exact evaluation of the fine phonatory vocal fold vibrations during vocalization, with impressive spatial portrayal of the mucosal wave in slow motion. However, because 3D laryngostroboscopy provides new information, different questions arise regarding the future diagnostic documentation. How can information beyond the standards of 2D laryngostroboscopy be systematically extracted and evaluated?

The qualitatively improved depth perception has a major impact on the correct assessment of the true position and movement of the vocal folds. It is known that the vocal folds level and motion are different in some diseases.^{35–37} In the 2D view from above, the vocal folds move medially toward each other, giving the impression of a complete closure of the glottis.³⁸ Because they are on a different level, they allow too much air to pass through the glottis, causing alterations of the normal vocal fold vibration cycle and dysphonia.^{39,40} In this case, the evaluation of the closing and closure process,

as well as the determination of symmetry between the left and right vocal fold, would be important. As assumed, the newly invented 3D imaging system can visualize such information. We therefore recommend a regular assessment of this parameter in future laryngeal diagnostics with the 3D system because we consider the symmetry and level of both vocal folds in relation to each other as a particularly important parameter for the clinical evaluation and optimized treatment planning.^{41,42} In this respect, a distinction should be made between the symmetry in the transversal versus the sagittal plane. Another possibly interesting variable seems to be the volume of various anatomical and pathological structures. Such conceivable volume calculations based on 3D laryngostroboscopy remain very exciting from the clinical perspective and can probably be realized using a pilot laser. However, this requires additional research effort, which should be pursued after clarification of the clinical need (e.g., in malignant diseases) and estimation of development costs.

In the future, it will also be essential to find out which additional features can increase the significance

of 3D endostroboscopy. It would be desirable to develop a 3D laryngostroboscope version with a reduced field of view and higher magnification of certain laryngeal sections to realize better visualization and safer assessment of very small details in the sub- and micromillimeter range. Imaginable for additional optimization of 3D-based diagnostic procedures is the combination with other established examination methods, such as electroacoustic voice analysis. Compared to the known electroglottography, an advanced examination instrument could be created.^{43,44} Furthermore, innovative endoscopic imaging techniques and new optical visualization modes are currently developed and tested to enhance the diagnostic sensitivity and specificity, especially in precancerous lesions.^{45–47} The long-term goal is the development of a multimodal system with rigid and flexible endoscopes for more comprehensive laryngostroboscopic examination. This system should combine the advantages of direct and indirect laryngoscopy and achieve significant improvements in imaging quality. New technologies such as 3D imaging and 4K format^{48,49} must be used to achieve this goal and allow the newly developed system to be the most modern laryngeal endostroboscopy system on the market. Due to the impressive results so far, the transfer of 3D endoscopy to other medical disciplines seems to be appropriate and desirable. The 3D stroboscopy will especially benefit laryngologists and phoniatricians but possibly also researchers who want to examine and capture fast-moving activities and motion sequences in other difficult-to-access body cavities (e.g., visualization of eardrum vibrations).

CONCLUSION

Three-dimensional laryngostroboscopy proved to be useful for understanding functional and surgical anatomy. The newly developed 3D system assists in more precise indication of phonosurgical interventions, increased accuracy of surgical planning, facilitated office-based endoscopic surgery, and better evaluation of prognostic factors for the outcome of phonosurgical procedures. Its application has enormous potential for improving the diagnostic value of laryngoscopy, surgical precision in laryngotracheal interventions, tissue preservation, and methods of teaching. Further clinical research is necessary concerning the benefits and advantages of the emerging 3D technology compared to standard 2D laryngostroboscopy.

BIBLIOGRAPHY

- Garcia M. Observations on the human voice. *Proc R Soc Lond* 1856;7:399–410.
- Brodnitz FS. One hundred years of laryngoscopy: to the memory of Garcia, Tuerck and Czermak. *Trans Am Acad Ophthalmol Otolaryngol* 1954;58:663–669.
- Bailey B. Laryngoscopy and laryngoscopes—who's first?: the forefathers/four fathers of laryngology. *Laryngoscope* 1996;106:939–943.
- Jahn A, Blitzer A. A short history of laryngoscopy. *Logoped Phoniatr Vocol* 1996;21:181–185.
- Merati AL, Rieder AA. Normal endoscopic anatomy of the pharynx and larynx. *Am J Med* 2003;115(suppl 3A):10S–14S.
- Mau T. Diagnostic evaluation and management of hoarseness. *Med Clin North Am* 2010;94:945–960.
- Mannelli G, Ceconi L, Gallo O. Laryngeal preneoplastic lesions and cancer: challenging diagnosis. Qualitative literature review and meta-analysis. *Crit Rev Oncol Hematol* 2016;106:64–90.
- Eller R, Ginsburg M, Lurie D, Heman-Ackah Y, Lyons K, Sataloff R. Flexible laryngoscopy: a comparison of fiber optic and distal chip technologies. Part 1: vocal fold masses. *J Voice* 2008;22:746–750.
- Verma SP, Dailey SH. Overcoming nasal discomfort—a novel method for office-based laser surgery. *Laryngoscope* 2011;121:2396–2398.
- Bliiss M, Muntz H. Nasal endoscopy: new tools and technology for accurate assessment. *Adv Otorhinolaryngol* 2015;76:18–26.
- Caffier PP, Schmidt B, Gross M, et al. A comparison of white light laryngostroboscopy versus autofluorescence endoscopy in the evaluation of vocal fold pathology. *Laryngoscope* 2013;123:1729–1734.
- Zacharias SR, Weinrich B, Brehm SB, et al. Assessment of vibratory characteristics in children following airway reconstruction using flexible and rigid endoscopy and stroboscopy. *JAMA Otolaryngol Head Neck Surg* 2015;141:882–887.
- Hosbach-Cannon CJ, Lowell SY, Kelley RT, Colton RH. A preliminary quantitative comparison of vibratory amplitude using rigid and flexible stroboscopic assessment. *J Voice* 2016;30:485–492.
- Dailey SH, Spanou K, Zeitels SM. The evaluation of benign glottic lesions: rigid telescopic stroboscopy versus suspension microlaryngoscopy. *J Voice* 2007;21:112–118.
- Akbulut S, Altintas H, Oguz H. Videolaryngostroboscopy versus microlaryngoscopy for the diagnosis of benign vocal cord lesions: a prospective clinical study. *Eur Arch Otorhinolaryngol* 2015;272:131–136.
- Young WG, Shama L, Petty B, Hoffman MR, Dailey SH. Comparing videostroboscopy and direct microlaryngoscopy: an argument for flexible consent and operative plan. *J Voice* 2017. doi: 10.1016/j.jvoice.2017.10.005.
- Rosen CA, Simpson CB. *Operative Techniques in Laryngology*. Berlin, Germany: Springer; 2008.
- Navka T, Martin A, Caffier PP. Microlaryngoscopy and phonosurgery. *HNO* 2013;61:108–116.
- Benjamin B, Lindholm CE. Systematic direct laryngoscopy: the Lindholm laryngoscopes. *Ann Otol Rhinol Laryngol* 2003;112:787–797.
- Barakate M, Maver E, Wotherspoon G, Havas T. Anaesthesia for microlaryngeal and laser laryngeal surgery: impact of subglottic jet ventilation. *J Laryngol Otol* 2010;124:641–645.
- Collins SR. Direct and indirect laryngoscopy: equipment and techniques. *Respir Care* 2014;59:850–864.
- Ogino-Nishimura E, Nakagawa T, Sakamoto T, Ito J. Efficacy of three-dimensional endoscopy in endonasal surgery. *Auris Nasus Larynx* 2015;42:203–207.
- Chan JYW, Wei WI. Three-dimensional endoscopy for endoscopic salvage nasopharyngectomy: preliminary report of experience. *Laryngoscope* 2017. doi: 10.1002/lary.26993.
- Zaidi HA, Zehri A, Smith TR, Nakaji P, Laws ER Jr. Efficacy of three-dimensional endoscopy for ventral skull base pathology: a systematic review of the literature. *World Neurosurg* 2016;86:419–431.
- Fuminari K, Hideki A, Manabu O, Mitsunori M. Extended endoscopic endonasal surgery using three-dimensional endoscopy in the intraoperative MRI suite for supra-diaphragmatic ectopic pituitary adenoma. *Turk Neurosurg* 2015;25:503–507.
- Fergo C, Burcharth J, Pommergaard HC, Kildebro N, Rosenberg J. Three-dimensional laparoscopy vs 2-dimensional laparoscopy with high-definition technology for abdominal surgery: a systematic review. *Am J Surg* 2017;213:159–170.
- Schwab K, Smith R, Brown V, Whyte M, Jourdan I. Evolution of stereoscopic imaging in surgery and recent advances. *World J Gastrointest Endosc* 2017;9:368–377.
- Reilly BK, Holliday MA, Rock AN, Kang X, Shekhar R, Preciado DA. Three-dimensional direct laryngoscopy and bronchoscopy: enhanced visualization of the airway. *JAMA Otolaryngol Head Neck Surg* 2013;139:367–370.
- Rosen CA, Murry T. Nomenclature of voice disorders and vocal pathology. *Otolaryngol Clin North Am* 2000;33:1035–1046.
- Bohr C, Dollinger M, Kniesburges S, Traxdorf M. 3D visualization and analysis of vocal fold dynamics. *HNO* 2016;64:254–261.
- Kawaida M, Fukuda H, Kohno N. New visualization technique with a three-dimensional video-assisted stereoendoscopic system: application of the BVHIS display method during endolaryngeal surgery. *J Voice* 2002;16:105–116.
- Shao J, Stern J, Wang ZM, Hanson D, Jiang J. Clinical evaluation of 70 degrees and 90 degrees laryngeal telescopes. *Arch Otolaryngol Head Neck Surg* 2002;128:941–944.
- Eryilmaz A, Akmansu H, Topcu E, Acar A, Korkmaz H. The role of 70-degree telescopic examination during direct laryngoscopic evaluation of laryngeal cancers. *Eur Arch Otorhinolaryngol* 2004;261:267–269.
- Van Gompel JJ, Tabor MH, Youssef AS, et al. Field of view comparison between two-dimensional and three-dimensional endoscopy. *Laryngoscope* 2014;124:387–390.
- Woo P, Isseroff TF, Parasher A, Richards A, Sivak M. Laryngeal electromyographic findings in patients with vocal fold motion asymmetry. *Laryngoscope* 2016;126:E273–E277.
- Stager SV. Vocal fold paresis: etiology, clinical diagnosis and clinical management. *Curr Opin Otolaryngol Head Neck Surg* 2014;22:444–449.
- Eysholdt U, Rosanowski F, Hoppe U. Vocal fold vibration irregularities caused by different types of laryngeal asymmetry. *Eur Arch Otorhinolaryngol* 2003;260:412–417.
- Bonilha HS, Desjardins M, Garand KL, Martin-Harris B. Parameters and scales used to assess and report findings from stroboscopy: a systematic review. *J Voice* 2017. doi: 10.1016/j.jvoice.2017.09.018.

39. Birk V, Kniesburges S, Semmler M, et al. Influence of glottal closure on the phonatory process in ex vivo porcine larynges. *J Acoust Soc Am* 2017;142:2197.
40. DeJonckere PH, Lebacqz J, Titze IR. Dynamics of the driving force during the normal vocal fold vibration cycle. *J Voice* 2017;31:649–661.
41. Vachha BA, Ginat DT, Mallur P, Cunnane M, Moonis G. "Finding a voice": imaging features after phonosurgical procedures for vocal fold paralysis. *AJNR Am J Neuroradiol* 2016;37:1574–1580.
42. Siu J, Tam S, Fung K. A comparison of outcomes in interventions for unilateral vocal fold paralysis: a systematic review. *Laryngoscope* 2016;126:1616–1624.
43. Titze IR, Story BH, Burnett GC, Holzrichter JF, Ng LC, Lea WA. Comparison between electroglottography and electromagnetic glottography. *J Acoust Soc Am* 2000;107:581–588.
44. Jing B, Chigan P, Ge Z, Wu L, Wang S, Wan M. Visualizing the movement of the contact between vocal folds during vibration by using array-based transmission ultrasonic glottography. *J Acoust Soc Am* 2017;141:3312.
45. Volgger V, Felicio A, Lohscheller J, et al. Evaluation of the combined use of narrow band imaging and high-speed imaging to discriminate laryngeal lesions. *Lasers Surg Med* 2017;49:609–618.
46. Betz CS, Kraft M, Arens C, et al. Optical diagnostic methods for early tumour diagnosis in the upper aerodigestive tract: quo vadis? *HNO* 2016;64:41–48.
47. Hawkshaw MJ, Sataloff JB, Sataloff RT. New concepts in vocal fold imaging: a review. *J Voice* 2013;27:738–743.
48. Rigante M, La Rocca G, Lauretti L, et al. Preliminary experience with 4K ultra-high definition endoscope: analysis of pros and cons in skull base surgery. *Acta Otorhinolaryngol Ital* 2017;37:237–241.
49. Woo P. 4K Video-Laryngoscopy and video-stroboscopy: preliminary findings. *Ann Otol Rhinol Laryngol* 2016;125:77–81.